PAUS
Pet Animal Ultrasound Service
4paus.com 781-635-5677

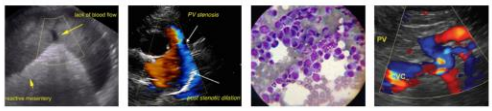

SonoPath
Clinical Sonography & Telecytology
EDUCATIONAL TELECONSULTATION SERVICES™
1-800-838-4268 info@sonopath.com SonoPath.com

PATIENT
Timmy Vanover

SPECIES
Feline

BREED
DSH

SEX
Male Intact

AGE
5 months

WEIGHT
7.9lbs

INTERPRETED BY
Maggie Machen Lamy, DVM DACVIM (Cardiology)

IMAGING PERFORMED BY
Pamela Harrigan, RDCS

HOSPITAL NAME
Wood River Animal Hospital

REFERRING VET
Dr. Fischer

INVOICE
23402

DATE
4/1/22

PRESENTING CLINICAL SIGNS

History: Grade lll/Vl holosystolic murmur, not heard immediately after birth and unchanged in past month. Unilateral cryptorchid and bob tail. BP: 220mmHg. *Sedated with butorphanol for study.

ECHOCARDIOGRAM FINDINGS

2D, m-mode, color flow and Doppler imaging is available.

Left ventricle: The LV diameter is normal with adequate myocardial function. The LV wall thicknesses are normal. Systolic septal flattening. There is a mildly hyperechoic endocardium. The papillary muscles are normal. The endocardium appears mildly remodeled.

Left atrium: The left atrium is normal in dimension. No obvious spontaneous contrast or thrombi seen.

Mitral valve: The mitral valve is normal in structure and mobility. No obvious systolic anterior motion is seen. No MR.

Aortic valve/Aorta: The aortic valve is normal in morphology and mobility. Normal aortic outflow velocity; laminar flow. No aortic insufficiency.

Right ventricle: The RV walls are severely hypertrophied. Exuberant fibrotic tissue is noted within the mid-RV, creating a significant stenosis through the region; most consistent with double chamber right ventricle/tunnel stenosis. An RVOTO is suspected as well due to significant RVH.

Right atrium: The right atrium is moderately dilated.

Tricuspid valve: The tricuspid valve appears normal with mild tricuspid regurgitation. Elevated velocity.

Pulmonic valve/Pulmonary artery: The pulmonic valve appears normal. Trivial pulmonic insufficiency.

Pericardium/other: No pericardial or pleural effusion noted. No obvious cardiac masses.

Heart rhythm: ECG reveals a sinus rhythm with an average HR of 150bpm.

2-Dimensional Measurements

Ao diam (cm)	0.8
LA diam (cm)	1.0
LA:Ao (Swe)	1.3
IVS thickness (cm)	0.39
LVID diastole (cm)	0.82
PW thickness (cm)	0.44
LVID systole (cm)	0.38
FS (%)	54

Doppler Measurements

RVOT Vmax (m/s)	4.4
AoV Vmax (m/s)	0.9
MR Vmax (m/s)	NA
TR Vmax (m/s)	5.0
TR PG (mmHg)	100

INTERPRETATION OF THE FINDINGS

The cause of the murmur is a significant stenosis through the mid-RV and a secondary RVOT obstruction. This is most consistent with a double chamber right ventricle/tunnel stenosis through the region. The velocity through the region is severely elevated and is creating an elevated TR velocity and severe RVH. No obvious additional issues are identified.

This finding as a whole is uncommon in small animals. These cases carry a high risk for complications lifelong, with many patients developing exertional syncope, right-sided CHF, blood clot events and/or sudden death by mid-life. A diagnostic angiogram should

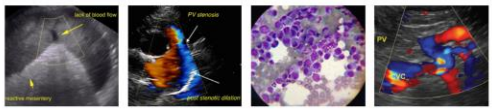

PATIENT
Timmy Vanover

SPECIES
Feline

BREED
DSH

SEX
Male Intact

AGE
5 months

WEIGHT
7.9lbs

INTERPRETED BY
Maggie Machen Lamy, DVM DACVIM (Cardiology)

IMAGING PERFORMED BY
Pamela Harrigan, RDCS

HOSPITAL NAME
Wood River Animal Hospital

REFERRING VET
Dr. Fischer

INVOICE
23402

DATE
4/1/22

be considered as the gold standard diagnostic tool, to confirm the diagnosis and further evaluate if any interventional options may be beneficial; however, in a kitten surgery is likely not a possibility regardless. As a more suitable approach, medical management with atenolol may be helpful in the future to decrease heart rate and lessen the obstruction and is recommended as below.

Prognosis is guarded to poor long-term, given the severity of RV changes at such a young age, with high risk for progression to right-sided CHF, syncope, malignant arrhythmias and/or sudden death lifelong.

RECOMMENDATIONS

- Administer titrating dose of atenolol: 25mg tablets; Give ¼ tab once daily in the evening. Recheck heart rate in 1-2 weeks with target stressed rate of 140-160bpm 12-24 hours post-administration. Increase as needed until target reached.
- If needed, anesthetic risk is considered elevated, and judicious IV fluid rates are advised avoid fluid overload. Pre-oxygenate for 5 minutes prior to induction and recover in O2 if possible. Drugs that stimulate heart rate should be avoided unless clinically necessary (glycopyrrolate, atropine). A reasonable protocol includes opioid/benzodiazepine premedication, propofol induction, isoflurane maintenance.
- Monitor heart rate, BP, ECG carefully and intervene as necessary.
- Monitor for any clinical evidence of cardiac compromise, including respiratory changes, abdominal distention, syncope, and/or signs of a blood clot event (paralysis, neurologic changes, etc.). Mild lifelong exercise restriction is advised.

PLAN

- Recommend recheck echocardiogram in 6-12 months to monitor rate of progression, sooner if clinical signs arise.

IMAGES

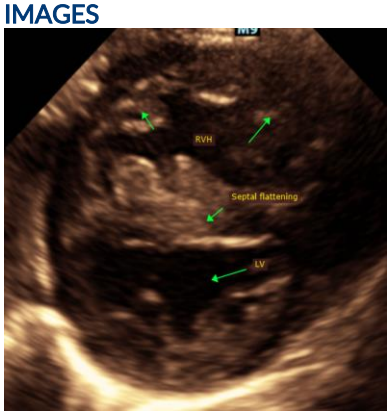

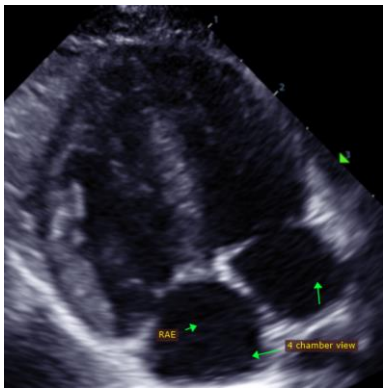

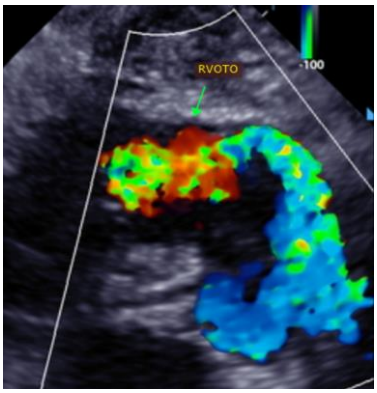

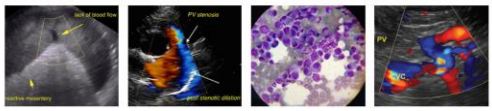

PATIENT
Timmy Vanover

SPECIES
Feline

BREED
DSH

SEX
Male Intact

AGE
5 months

WEIGHT
7.9lbs

INTERPRETED BY
Maggie Machen Lamy, DVM DACVIM (Cardiology)

IMAGING PERFORMED BY
Pamela Harrigan, RDCS

HOSPITAL NAME
Wood River Animal Hospital

REFERRING VET
Dr. Fischer

INVOICE
23402

DATE
4/1/22

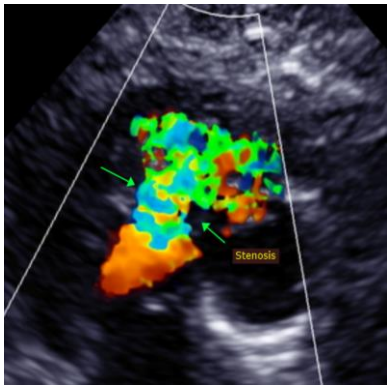

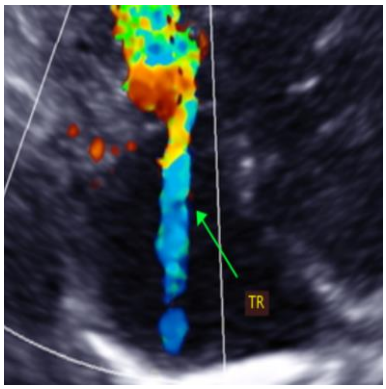

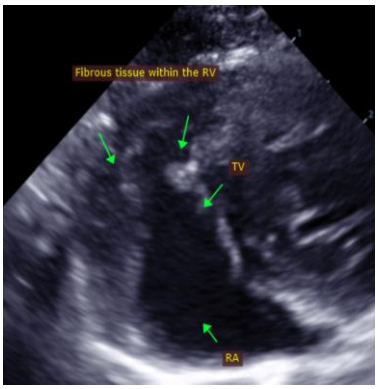

The information and recommendations provided are based on the images presented by the referring veterinarian. No evaluation can be communicated regarding pathology that was not visible in the image/video clips provided.

Thank you for this referral. This report was generated using transcription software, and minor dictation errors may be present. If the clinical or image interpretation does not parallel your findings or if I can be of any further assistance, please contact me.

Maggie Machen Lamy, DVM
Diplomate of the American College of Veterinary Internal Medicine (Cardiology)
info@sonopath.com